



## Summary Feedback

### ST1 – ST4 Teaching Programme 2023

### DKT FRCR 2B Practice Viva (Session 40)

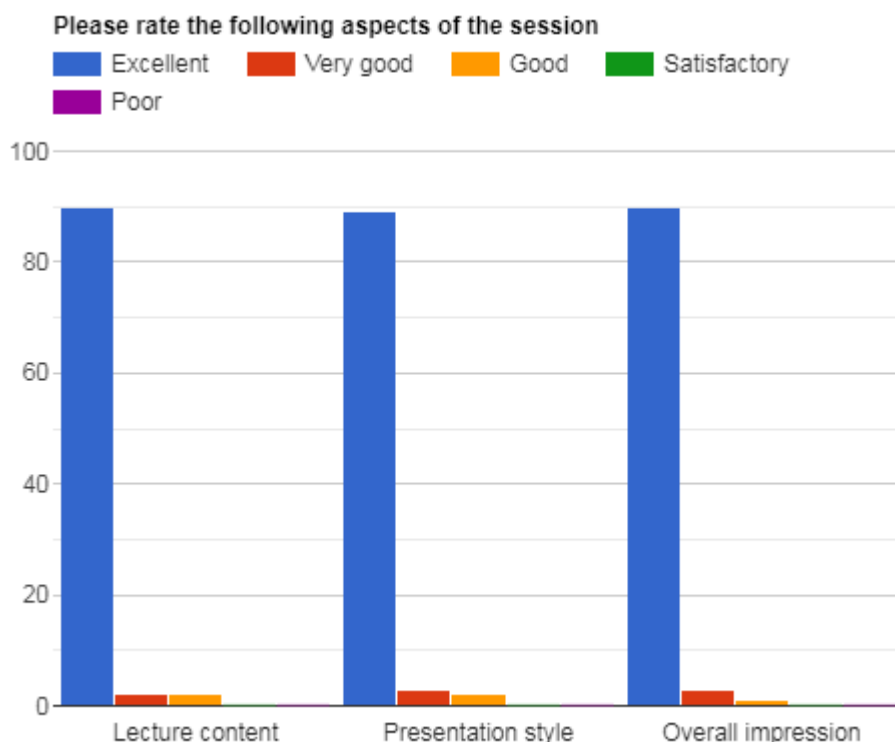
(9<sup>th</sup> November 2023)

Delivered By:

(Muhammad Iftikhar Rashid)

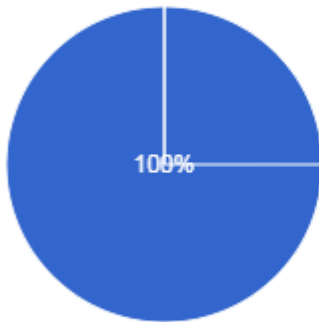
#### Summary Points:

- ST1-ST4 teaching programme 2023 – FRCR 2B Practice Viva Session 40: 2 hours teaching time
- Total Attendees: 254 from 31 Countries (Algeria, Australia, Bahrain, China, Czech Republic, Dominica, Egypt, Hong Kong, India, Indonesia, Iraq, Jordan, Kenya, Lebanon, Malaysia, Malta, Myanmar, Nigeria, Oman, Pakistan, Qatar, Saudi Arabia, South Africa, Sri Lanka, Sudan, Türkiye, UAE, UK, Yemen, Zambia, Zimbabwe).
- Total feedback received from 94 participants



Did you find it useful  
94 responses

● Yes  
● No



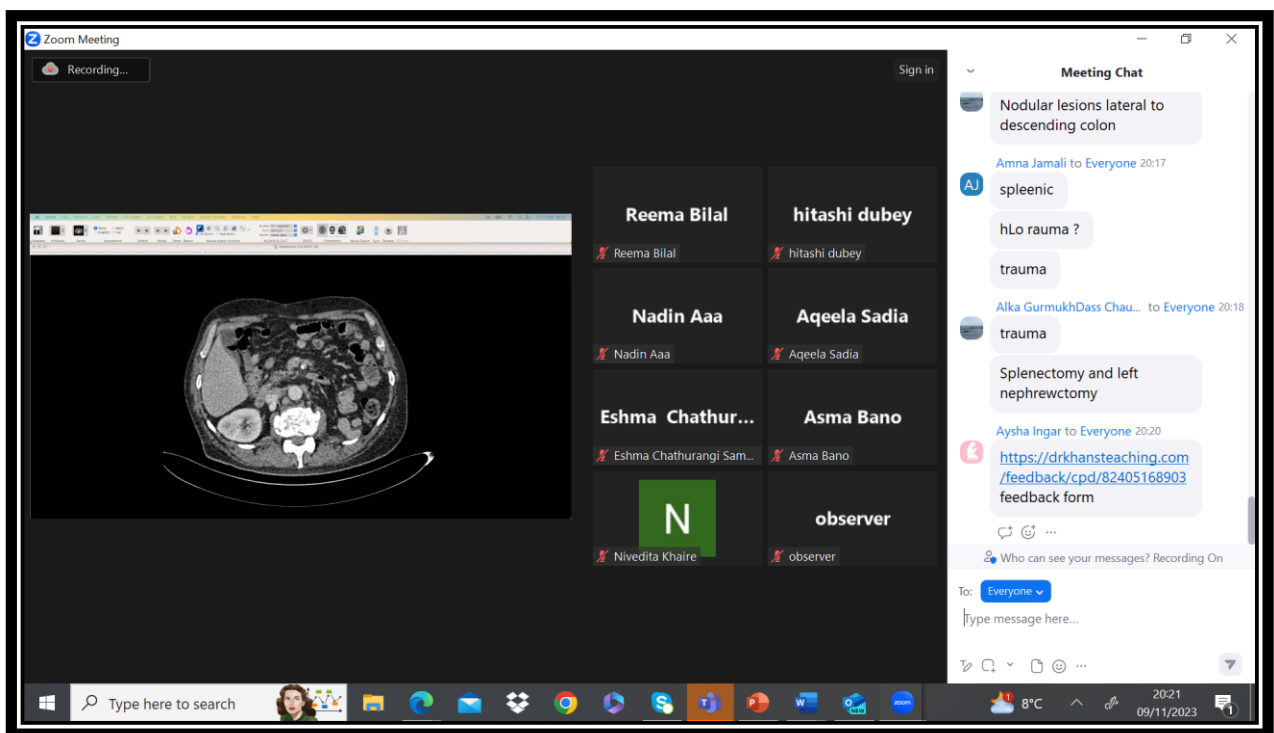
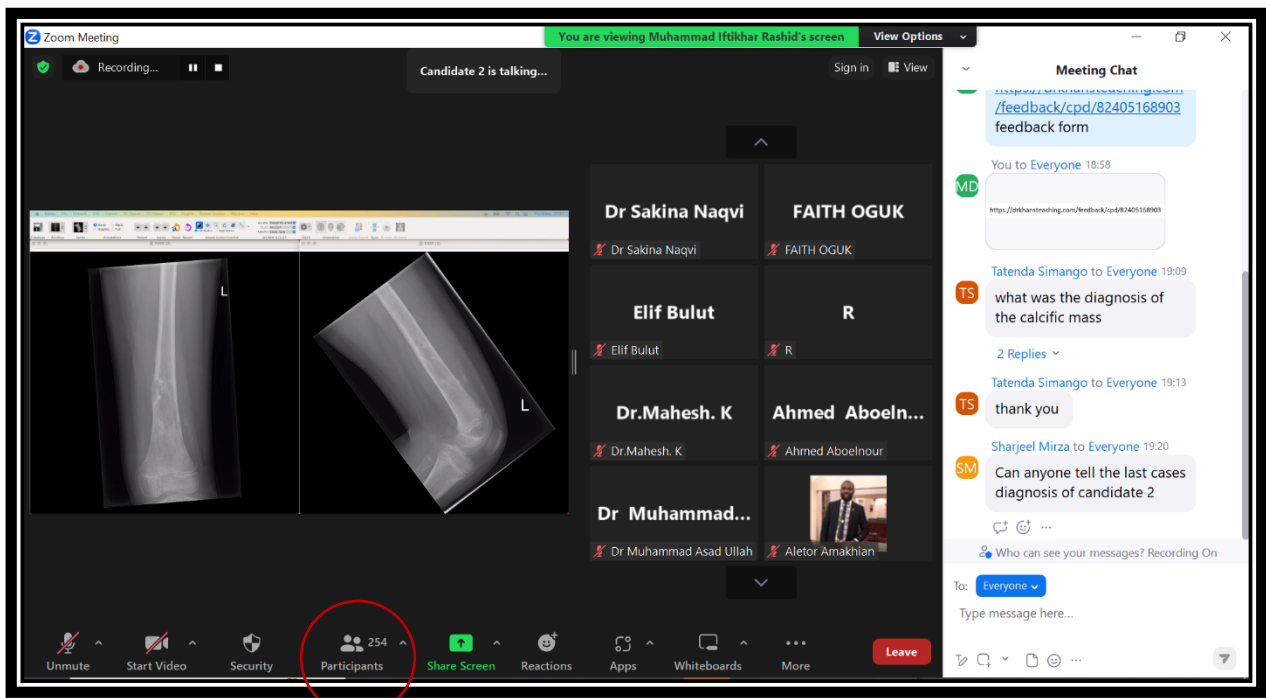
## Testimonials

- Everything is perfect in this session, Dr. Muhammad Iftikhar is loud and clear present to us plenty of interesting cases, and teach us how to narrow our differential and use everything in the image like the age of the patient and clinical history to narrow our differential with great explanation on each case in details (Jordan).
- We need more sessions, especially with amazing lecturer like him (Saudi Arabia).
- More sessions from Dr Iftakar on plain film-based cases. These are really helpful in exams in real time (India).
- Brilliant session by Dr Iftakar. Real time exam scenario cases (India).
- Excellent session, brilliant explanation good cases practical points were discussed, very thankful for the session (Pakistan).
- All cases were great! very informative. Indepth discussion on cases was very helpful! (India).
- I liked the cases variety and enriching discussion (India).
- Excellent mix of cases, very exam oriented. These types of cases build your observation skills and help you sail through the exam (India).
- I liked the variety of cases and teaching points (Lebenon).
- Dr. M.I. Rashid, a excellent teacher, very patient examiner and a great doctor (Iraq).
- I liked the brief review of various concepts (Türkiye).
- This was brilliant (UK).
- Excellent cases and discussion. Very informative session (Egypt).
- Amazing cases and lecturer (Saudi Arabia).
- Wonderful cases (Egypt).

## DKT FRCR 2B Practice Viva (Session 40)

- Great source of learning (UK).
- Perfect (Saudi Arabia).
- Highly impressed (UK).
- Woow (Egypt).
- Excellent session (Pakistan).
- Good cases (UK).
- I liked the spectrum of cases (UAE).
- Viva cases variety was useful (UK).
- Every aspect was valauble (Pakistan).
- Good discussion (Sri Lanka).
- All are valuable (UK).
- Teaching material was useful (UAE).
- Good collection (Qatar).
- Perfect (Pakistan).
- Questions asked by the examiner relavent to case were useful (Sri Lanka).
- Good cases and nice explanation (Pakistan).
- Nice variety of cases (Türkiye).
- Everything was useful (Oman).
- Very good cases (Egypt).
- Cases were excellent (Saudi Arabia).
- Very good exam cases and tips (Pakistan).
- Cases were very well explained (Kenya).
- Brilliant collection of plain film selection (Sri Lanka)
- Train the eye to pick up subtle findings was valuable part of the session (Qatar).
- As always it's good (UK).
- Very good choice of cases (Pakistan).
- Wide variety of cases and the way of cases interpretation is excellent (Egypt).
- Overall wonderful (UAE).
- Very informative (UAE).
- Amazing (Saudi Arabia).
- Excellent lecture (Sri Lanka).
- Excellent session (Pakistan).
- Excellent teaching session (ALgeria).
- Very educative (Kenya).
- Very useful and informative (Saudi Arabia).
- Excellent session and brilliant cases by Dr Iftikhar (Pakistan).
- Excellent discussion and interpretation of cases (Egypt).
- Excellent (Indonesia).

# DKT FRCR 2B Practice Viva (Session 40)



# DKT FRCR 2B Practice Viva (Session 40)

The screenshot shows a Zoom meeting in progress. The main content area displays two X-ray images of the spine, one anterior and one lateral view. A participant grid on the right lists several names, including Asma Bano, Nivedita Khairi, Sharjeel Mirza, Abhinav Bhagat, Kasuni Gunaratna, Rashid Hussain, and Farah Sana. A chat window on the far right contains the following text:

Meeting Chat

Nodular lesions lateral to descending colon

Amna Jamali to Everyone 20:17

splenic trauma

hLo rauma ?

Alka GurmukhDass Chau... to Everyone 20:18

trauma

Splenectomy and left nephrectomy

Aysha Ingar to Everyone 20:20

<https://drkhansteaching.com/feedback/cpd/B2405168903> feedback form

Who can see your messages? Recording On

To: Everyone

Type message here...

=====XX=====XX=====